



Musculoskeletal Monthly

An evidence-based newsletter related to the management of musculoskeletal disorders

The role of imaging and its utilization in the management of low back pain

Lumbar spine radiography is the most common investigation undertaken for low back pain (LBP) in primary care.¹ In addition, among some specialties the use of radiography for patients with LBP is influenced little by clinical presentation.² The main purpose of lumbar spine imaging is to rule-out “red flag” causes of LBP such as malignancies, infections, inflammatory spondyloarthropathies and fractures.³ More recently, advances in Magnetic Resonance Imaging (MRI) have made it an attractive substitute to plain radiographs with the hope that it may lead to a swifter definitive diagnosis and screening for systemic disease.⁴ As with all interventions and diagnostic tests, the risk-benefit ratio should justify whatever procedures are used. Given the frequency of use and associated costs, one must ask “Is this the case with imaging for LBP?”

Before answering the preceding question, it is first helpful to remind ourselves (yet again) of some relevant common facts about LBP presenting in a primary care setting: a. 80% of LBP is non-specific or mechanical in nature for which a definitive pathoanatomic diagnosis can't be established;⁵ b. In selected cases, certain injured structures (degenerated discs and facts (10%), herniated discs (4%), spinal stenosis (3%) and other bony abnormalities) can give rise to mechanical LBP and leg pain but these abnormalities are common in persons without symptoms as well;⁶ c. serious spinal conditions are rare and comprise < 2% of presenting cases.⁷ Although the large majority of patients with LBP improve substantially within a month, recurrent lingering pain and additional health care seeking at 6 months are common⁸ in patients who aren't matched with appropriate intervention⁹⁻¹¹ and 1/3 of primary care patients treated in a primary care setting seek care from multiple providers.¹²

Having the clinical context of LBP outlined makes it easier to answer the pertinent questions regarding imaging, which are: diagnostic accuracy, associated risks, and outcomes.

- **Diagnostic accuracy:** Precise estimates are unavailable due to questions of reference criteria and study biases. However, the following summary by Beattie and Meyers¹³ are relevant and remain unaltered by more recent reports:

1. Disc degeneration is more pronounced with age and is equally common in persons with and without LBP.³ In persons without LBP, it is present in 77% of persons aged 35-45yrs and in everyone older than 65.¹⁴
2. Disc bulging and herniation are both prevalent in persons with and without LBP (27 – 52%)^{3,6}
3. Disk extrusion is uncommon in people without LBP (2 – 6%),¹⁴ but is more likely to be diagnostically and clinically relevant in persons with LBP, especially those who have more than 5 previous episodes (30%).¹⁴⁻¹⁶
4. Minor nerve root compromise (contact with nerve or thecal sac) is common in persons without LBP. However, major neural compromise (actual compression) is uncommon in individuals with LBP but is common in patients whose symptoms warrant lumbar MRI.^{14, 15, 17, 18}

In addition, spondylolysis and spondylolesthesis, spina bifida, transitional vertebrae, spondylosis, and Scheuermann's disease do not appear to be associated with LBP.³

- **Risk:** The first consideration that comes to mind is ionizing radiation, especially with oblique views (double the exposure of standard views) on younger female patients.¹⁹ However, patients who are informed of abnormalities identified on requested radiographs may have an associated increase in pain²⁰ and in the case of MRI, this may lead to an increased likelihood of surgery^{4,21} with little, if any, additional benefit.

- **Outcomes:** At least 2 high quality randomized clinical trial have demonstrated that the use of lumbar radiography results in no difference in clinically meaningful health status outcomes for patients with LBP.¹ Similarly, there is no difference in back related disability measures when MRI vs plain radiography is used⁴ Patients who receive plain radiography may experience greater patient satisfaction (1 point at a cost of \$90.17)¹ but at the risk stated above

In summary, based on the current best-evidence for the role of imaging and LBP: 1. There is a high prevalence of abnormal findings in persons with and without LBP; 2. It is not possible to establish a causal relationship between radiographic findings *alone* and non-specific LBP; 3. Some findings are more common in patients with LBP complaints and these include disc extrusions and major nerve compression; 4. MRI abnormalities are not predictive of future LBP episodes;^{15, 22}, and 5. Questions remain regarding diagnostic accuracy.

DEPRESSION SCREENING QUESTIONS
1. → During the past month, have you often been bothered by feeling down, depressed, or hopeless?
2. → During the past month, have you often been bothered by little interest or pleasure in doing things?

Figure 1: Two Depression Screening Questions

MRI has not improved outcomes in patients with non-specific LBP, and in doing so joins the ranks of appealing innovations that have prove illusory. Despite the results of numerous high quality radiologic studies since the 1994 Agency for Health Care Policy and Research Guidelines for LBP have been published, they remain the standard: Imaging should be reserved for those patients considered to be surgical candidates or in whom systemic illness is suspected.²³

In the majority of patients suffering from LBP, imaging is not indicated nor helpful and a precise cause remains elusive. Identifying depression is a more important task and better predictor of patients at risk for developing poorer outcomes²⁴ and subsequent episodes of LBP once their condition has resolved (hazards ration= 2.3).⁴ The good news is that patients with LBP can achieve a highly successful outcome when managed with a treatment based classification approach.^{9-11, 25} and 2 simple questions are useful for identifying depressed patients at risk (-LR ≤.25) (Figure 1).^{15, 26, 27} We at

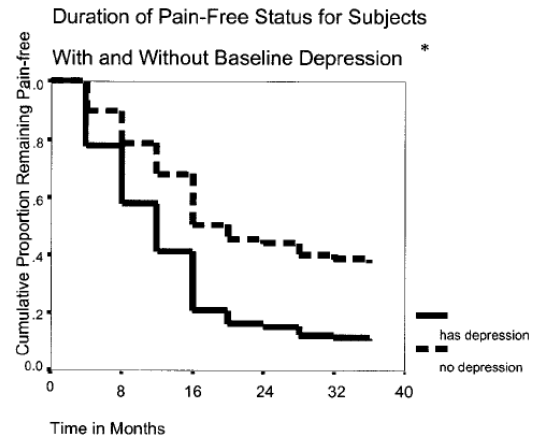


Figure 2: Depression and development of LBP

Robert S. Wainner, PT, PhD, OCS, ECS, FAAOMPT

John D. Childs, PT, PhD, MBA, OCS, FAAOMPT

1. Miller P, Kendrick D, Bentley E, Fielding K. Cost-effectiveness of lumbar spine radiography in primary care patients with low back pain. *Spine* 2002;27(20):2291-7.
2. Carey TS, Garrett J. Patterns of ordering diagnostic tests for patients with acute low back pain. The North Carolina Back Pain Project. *Ann Intern Med* 1996;125(10):807-14.
3. van Tulder MW, Assendelft WJ, Koes BW, Bouter LM. Spinal radiographic findings and nonspecific low back pain. A systematic review of observational studies. *Spine* 1997;22(4):427-34.
4. Jarvik JG, Hollingworth W, Martin B, et al. Rapid magnetic resonance imaging vs radiographs for patients with low back pain: a randomized controlled trial. *Jama* 2003;289(21):2810-8.
5. Deyo RA, Phillips WR. Low back pain: A primary care challenge. *Spine* 1996;21(24):2826-32.
6. Jarvik JG, Deyo RA. Diagnostic evaluation of low back pain with emphasis on imaging. *Ann Intern Med* 2002;137(7):586-97.
7. Deyo RA, Weinstein JN. Low back pain. *N Engl J Med* 2001;344(5):363-70.
8. Croft PR, Macfarlane GJ, Papageorgiou AC, Thomas E, Silman AJ. Outcome of low back pain in general practice: a prospective study. *Bmj* 1998;316(7141):1356-9.
9. Childs JD, Fritz JM, Flynn T, Irrgang JJ, Delitto A, Johnson KK. Validation of a clinical prediction rule to identify patients with low back pain likely to benefit from spinal manipulation: A validation study. *Ann Intern Med* 2004;141(12):920-8.
10. Fritz J, Delitto A, Erhard RE. Comparison of classification-based physical therapy with therapy based on clinical practice guidelines for patients with acute low back pain: a randomized clinical trial. *Spine* 2003;28(13):1363-71.
11. Long A, Donelson R, Fung T. Does it Matter Which Exercise? A Randomized Control Trial of Exercise for Low Back Pain. *Spine* 2004;29(23):2593-602.
12. Sundararajan V, Konrad TR, Garrett J, Carey T. Patterns and determinants of multiple provider use in patients with acute low back pain. *J Gen Intern Med* 1998;13(8):528-33.
13. Beattie PF, Meyers SP. Magnetic resonance imaging in low back pain: general principles and clinical issues. *Phys Ther* 1998;78(7):738-53.
14. Jarvik JJ, Hollingworth W, Heagerty P, Haynor DR, Deyo RA. The Longitudinal Assessment of Imaging and Disability of the Back (LAIDBack) Study: baseline data. *Spine* 2001;26(10):1158-66.
15. Jarvik JG, Hollingworth W, Heagerty PJ, Haynor DR, Boyko EJ, Deyo RA. Three-year incidence of low back pain in an initially asymptomatic cohort: clinical and imaging risk factors. *Spine* 2005;30(13):1541-8; discussion 9.
16. Jensen MC, Brant-Zawadzki MN, Obuchowski N, Modic MT, Malkasian D, Ross JS. Magnetic resonance imaging of the lumbar spine in people without back pain. *N Engl J Med* 1994;331(2):69-73.
17. Boos N, Rieder R, Schade V, Spratt KF, Semmer N, Aebi M. 1995 Volvo Award in clinical sciences. The diagnostic accuracy of magnetic resonance imaging, work perception, and psychosocial factors in identifying symptomatic disc herniations. *Spine* 1995;20(24):2613-25.
18. Thornbury JR, Fryback DG, Turski PA, et al. Disk-caused nerve compression in patients with acute low-back pain: diagnosis with MR, CT myelography, and plain CT. *Radiology* 1993;186(3):731-8.
19. Antoku S, Russell WJ. Dose to the active bone marrow, gonads, and skin from roentgenography and fluoroscopy. *Radiology* 1971;101(3):669-78.
20. Kendrick D, Fielding K, Bentley E, Kerslake R, Miller P, Pringle M. Radiography of the lumbar spine in primary care patients with low back pain: randomised controlled trial. *Bmj* 2001;322(7283):400-5.
21. Lurie JD, Birkmeyer NJ, Weinstein JN. Rates of advanced spinal imaging and spine surgery. *Spine* 2003;28(6):616-20.
22. Borenstein DG, O'Mara JW, Jr., Boden SD, et al. The value of magnetic resonance imaging of the lumbar spine to predict low-back pain in asymptomatic subjects: a seven-year follow-up study. *J Bone Joint Surg Am* 2001;83-A(9):1306-11.
23. Bigos S, Bowyer O, G. B, al. E. Acute Low Back Problems in Adults. Clinical Practice Guideline 14. In: Servcies USDoHaH, ed.: Agency for Health Care Policy and Research; 1994:36-7.
24. Levy HI, Hanscom B, Boden SD. Three-question depression screener used for lumbar disc herniations and spinal stenosis. *Spine* 2002;27(11):1232-7.
25. OSullivan PB, Twomey LT, Allison GT. Evaluation of specific stabilizing exercise in the treatment of chronic low back pain with radiologic diagnosis of spondylolysis or spondylolisthesis. *Spine* 1997;22:2959-67.
26. Arroll B, Goodyear-Smith F, Kerse N, Fishman T, Gunn J. Effect of the addition of a "help" question to two screening questions on specificity for diagnosis of depression in general practice: diagnostic validity study. *Bmj* 2005;331(7521):884.
27. Haggman S, Maher CG, Refshauge KM. Screening for symptoms of depression by physical therapists managing low back pain. *Phys Ther* 2004;84(12):1157-66.